



Patient

NHS No

D.O.B.

Patient Ref

Reason

Routine

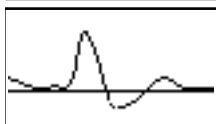
Outcome

Poor images, patient habitus, Patent

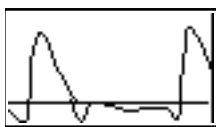Right

110

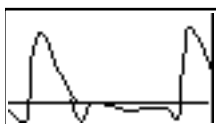
1.00



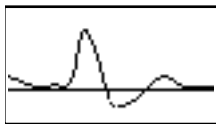
Good



Good



Slightly Reduced



Good

110

1.00

Brachial

Common Femoral

High Thigh

Low Thigh

Popliteal

High Calf

Peroneal

Anterior Tibial

Posterior Tibial

Dorsalis Pedis

Toe Pressure

Post Exercise

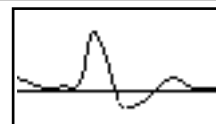
Foot Flex

110

1.00

Left

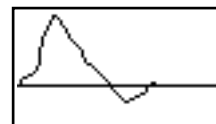
Good



Good

110

1.00



Notes

RIGHT LOWER LIMB ARTERIAL DUPLEX SCAN

Difficult assessment due to patient's body habitus, depth of vessels and sub-optimal image resolution.

AORTA: appears patent, good triphasic waveforms, PSV 98cm/s. Aorta is of normal calibre, maximal TS 1.7cm.

CIA: Difficult to visualise due to above outlined limitations, but where seen appears patent, good triphasic waveforms, PSV 167cm/s.

Assessed by

Lukasz Koprowski

Checked by



Patient

NHS No

D.O.B.

Patient Ref

EIA: Appears patent, good triphasic waveforms, PSV 198cm/s.

CFA: Appears widely patent, good triphasic waveforms, PSV 167cm/s.

PFA: Appears widely patent, good triphasic waveforms, PSV 94cm/s.

SFA: Appears patent throughout its length, but is difficult to track in the mid-distal thigh, good triphasic waveforms, PSV 91-119cm/s.

POPA: Appears widely patent, good triphasic waveforms, PSV 51cm/s.

TPT: Appears patent, with 2 vessel run-off identified.

ATA: Appears widely patent, slightly reduced bi/triphasic waveforms, PSV 34cm/s.

PTA: Appears widely patent, good triphasic waveforms, PSV 55cm/s.

PerA: not identified ?patency.

LEFT CFA: Appears widely patent, good triphasic waveforms, PSV 172cm/s.

ABPI: Bilateral, resting ABPIs are within normal limits, with no reduction observed on the right following exercise.

Assessed by

Lukasz Koprowski

Checked by
